



## Review article

Neural architectures of music – Insights from acquired amusia<sup>☆</sup>Aleksi J. Sihvonen<sup>a,b,\*</sup>, Teppo Särkämö<sup>b</sup>, Antoni Rodríguez-Fornells<sup>c</sup>, Pablo Ripollés<sup>d</sup>, Thomas F. Münte<sup>e</sup>, Seppo Soinila<sup>f</sup><sup>a</sup> Department of Neurosciences, University of Helsinki, Finland<sup>b</sup> Cognitive Brain Research Unit, Department of Psychology and Logopedics, University of Helsinki, Finland<sup>c</sup> Department of Cognition, University of Barcelona, Cognition & Brain Plasticity Unit, Bellvitge Biomedical Research Institute (IDIBELL), Institutió Catalana de recerca i Estudis Avançats (ICREA), Barcelona, Spain<sup>d</sup> Department of Psychology, New York University and Music and Audio Research Laboratory, New York University, USA<sup>e</sup> Department of Neurology and Institute of Psychology II, University of Lübeck, Germany<sup>f</sup> Division of Clinical Neurosciences, Turku University Hospital, Department of Neurology, University of Turku, Finland

## ARTICLE INFO

## Keywords:

Acquired amusia

Music

Stroke

Lesions

## ABSTRACT

The ability to perceive and produce music is a quintessential element of human life, present in all known cultures. Modern functional neuroimaging has revealed that music listening activates a large-scale bilateral network of cortical and subcortical regions in the healthy brain. Even the most accurate structural studies do not reveal which brain areas are critical and causally linked to music processing. Such questions may be answered by analysing the effects of focal brain lesions in patients' ability to perceive music. In this sense, acquired amusia after stroke provides a unique opportunity to investigate the neural architectures crucial for normal music processing. Based on the first large-scale longitudinal studies on stroke-induced amusia using modern multi-modal magnetic resonance imaging (MRI) techniques, such as advanced lesion-symptom mapping, grey and white matter morphometry, tractography and functional connectivity, we discuss neural structures critical for music processing, consider music processing in light of the dual-stream model in the right hemisphere, and propose a neural model for acquired amusia.

## 1. Introduction

The ability to perceive, enjoy, and produce music is a core element of human civilization, present in all cultures throughout history. Attempts to unravel the neural structures underlying music processing have been booming during the past two decades and studies have revealed a large-scale music processing network comprising bilateral temporal, frontal, parietal, and subcortical regions (for recent meta-analyses and reviews, see Zatorre and Salimpoor, 2013; Koelsch, 2014; Gordon et al., 2018; Freitas et al., 2018). While distinct brain areas involved in music processing have been identified in healthy subjects, the evidence derived from functional neuroimaging studies is largely correlational. Thus, the question of which brain areas are critical for music perception has remained elusive. Throughout the history of neuroscience and neurology, lesion-based studies have provided the opportunity to explore the relationships between the lesioned brain areas and specific cognitive or motor functions (Rorden and Karnath,

2004; Adolphs, 2016).

A specific neurological deficit known as amusia (the severe impairment of music perception and/or production not caused by general cognitive, perceptual, or motor disability) was first reported at the end of the 19<sup>th</sup> century (Graziano and Johnson, 2015). There are essentially two types of amusia: congenital amusia (CA), which is a neurodevelopmental disorder, and acquired amusia (AA), which is caused by brain damage resulting from a neurological disorder. While both CA and AA share the core symptoms of amusia, their neural mechanisms are likely to differ: CA is a developmental deficit in acquiring musical syntax and tonal representations that hampers the early development of the music processing network and leads to lifelong, often heterogeneous impairments with music (Stewart, 2008; Omigie et al., 2012). In contrast, AA reflects a clear-cut transition from a previously normal to a deficient music processing system caused by a brain lesion (e.g. stroke). This transition creates a unique opportunity to examine and pin down the neural structures that are most critical – and causally linked – to

<sup>☆</sup> All authors have been involved in drafting or revising the article critically for intellectual content and have read and approved the final version of the manuscript.

\* Corresponding author at: Cognitive Brain Research Unit, Department of Psychology and Logopedics, Haartmaninkatu 3, P.O. Box 21, FI-00014 University of Helsinki, Finland.

E-mail address: [aleksi.sihvonen@helsinki.fi](mailto:aleksi.sihvonen@helsinki.fi) (A.J. Sihvonen).

<https://doi.org/10.1016/j.neubiorev.2019.08.023>

Received 13 March 2019; Received in revised form 27 August 2019; Accepted 29 August 2019

Available online 31 August 2019

0149-7634/ © 2019 The Authors. Published by Elsevier Ltd. This is an open access article under the CC BY-NC-ND license

(<http://creativecommons.org/licenses/by-nc-nd/4.0/>).

music perception (Price and Friston, 2002; Rorden and Karnath, 2004).

The neural basis of CA has been relatively well mapped using modern structural neuroimaging methods, such as voxel-based morphometry (VBM) and diffusion tensor imaging (DTI), as well as functional and neurophysiological neuroimaging methods, including electroencephalography (EEG) and magnetoencephalography (MEG) and functional MRI (fMRI; for recent reviews, see Tillmann et al., 2015; Peretz, 2016). Studies on CA have provided evidence of reduced white matter concentration and abnormalities in grey matter volume (GMV) or cortical thickness in the inferior frontal gyrus (IFG) and the superior temporal gyrus (STG), predominantly in the right (Hyde et al., 2006, 2007; Albouy et al., 2013) but also in the left (Mandell et al., 2007) hemisphere. In addition, CA has been associated with reduced volume of the arcuate fasciculus (AF) interconnecting these frontotemporal structures (Loui et al., 2009). However, conflicting DTI results have been published leaving the tract deficit evidence in CA unsettled (Chen et al., 2015). There is also some controversy regarding the functional role of the auditory cortex in CA, with fMRI and MEG studies indicating either normal (Hyde et al., 2011; Norman-Haignere et al., 2016) or abnormal (Albouy et al., 2013, 2015; Albouy et al., 2019) processing of pitch changes or tonal memory in the right STG. However, current evidence suggests that in CA conscious attention to and cognitive analysis of musical pitch information in right frontal regions, especially in the IFG, fails due to reduced functional connectivity between the IFG and STG (Peretz et al., 2005, 2009; Hyde et al., 2011; Albouy et al., 2015; Zendel et al., 2015; Leveque et al., 2016; Norman-Haignere et al., 2016). CA is currently considered as a disconnection syndrome caused by anomalous recurrent processing in the right frontotemporal (dorsal) network (Peretz, 2016).

In contrast to CA, the exploration of the neural basis of AA has previously been limited to descriptive symptom-led studies of individual cases and lesion-led studies of patient groups (for a review, see Stewart et al., 2006). Methodologically, these studies have been limited by small sample sizes and by both low temporal (data collected only from a single time point) and spatial accuracy, with lesion areas reported at gross (lobar, hemispheric) anatomical level and not quantified. Consequently, the conclusions on the location and laterality of the lesion and the type of consequent musical deficit have been coarse and inconsistent. As shown in Fig. 1, which is an updated figure of the previous distinguished review on AA by Stewart et al. (2006), the lesion sites reported in previous case and group studies include multiple temporal, frontal, parietal, insular, and striatal areas in both left and right hemispheres (see also Supplementary Tables 1 and 2). The lesioned areas largely overlap for deficits in spectral (e.g., pitch, timbre) and temporal (e.g., rhythm, tempo) musical features, although right temporal lesions are predominant, especially for spectral deficits. The few EEG and MEG studies of AA stroke patients have used auditory oddball paradigms and shown reduced evoked responses to novel sounds reflecting impaired attentional processing (P3a, P3b; Münte et al., 1998; Johannes et al., 1998) and to pitch and duration changes reflecting impaired auditory sensory memory (MMN; Kohlmetz et al., 2001; Särkämö et al., 2010), but have not localized the neural sources of these aberrant responses.

Modern neuroimaging methods, including voxel-based lesion-symptom mapping (VLSM; a method that goes beyond single case studies to identify brain regions that cause specific symptoms when lesioned), VBM, DTI, and fMRI have been utilized to map the structural and functional neural correlates of AA in studies published only very recently. In this article, we review the current knowledge about the neural basis of AA and its recovery, and we briefly outline a neural model of the key structural and functional changes in AA and discuss their role in the recovery process and in light of normal music processing.

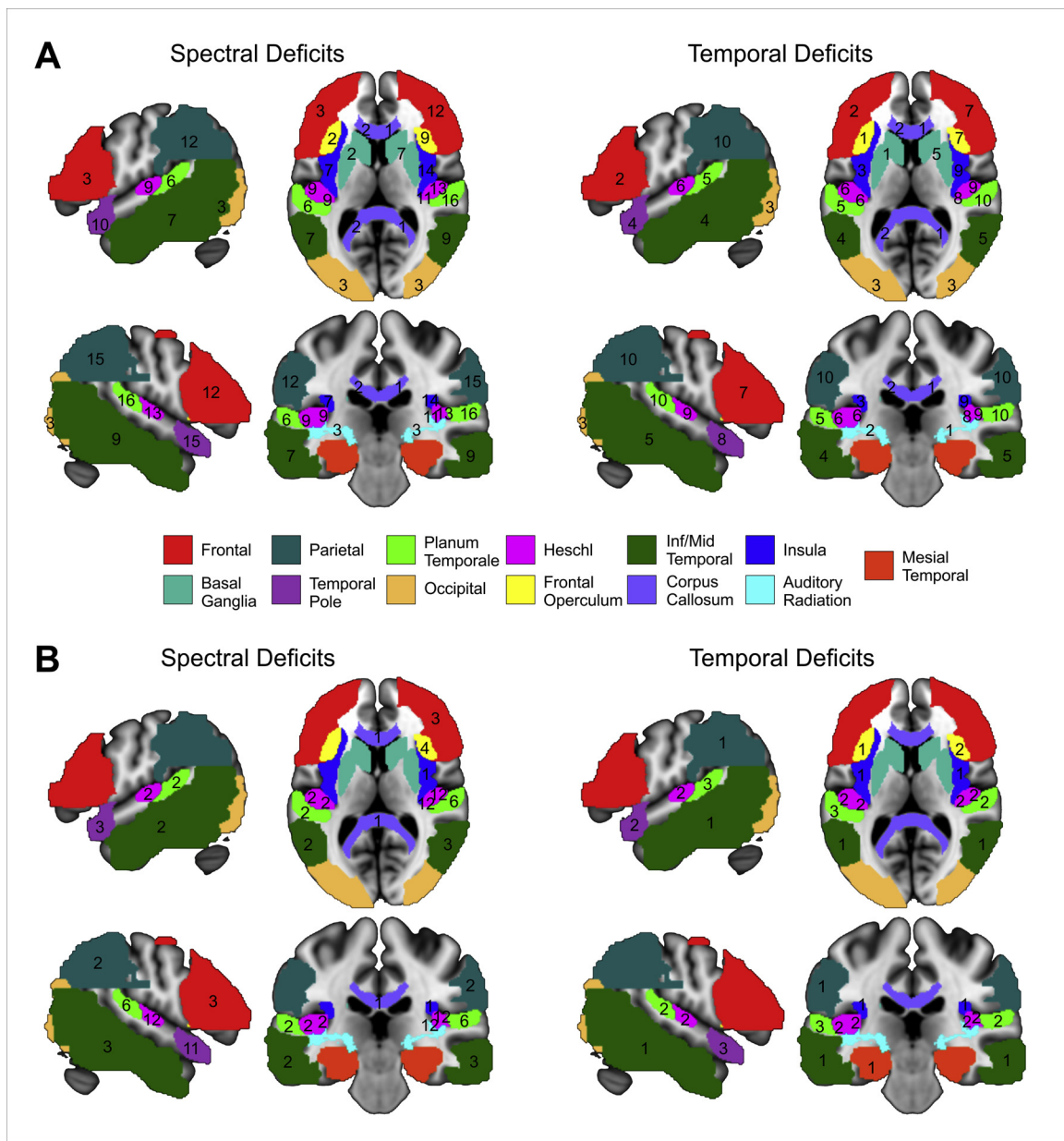
## 2. Structural and functional neural correlates of acquired amusia

### 2.1. Voxel-based lesion-symptom mapping

Lesion-symptom relationships can be explored with VLSM, which uses the same voxel-based approach as other neuroimaging techniques (Bates et al., 2003). Since 2004, VLSM has been successfully used in uncovering the lesion patterns of aphasia (Dronkers et al., 2004; Geva et al., 2012; Mirman et al., 2015), but it has been applied in AA only recently. In two studies of stroke patients (Sihvonen et al., 2016, 2017a) VLSM was used in conjunction with Scale and Rhythm subtests of the Montreal Battery of Evaluation of Amusia (MBEA; Peretz et al., 2003), gold standard assessment for amusia, and in one study (Hirel et al., 2017) with a music (melodic) short-term memory task similar to the MBEA. In their study of 20 chronic stroke patients, Hirel et al. (2017) found that lesions in the insula and frontoparietal operculum were associated with deficits in performing the music task, but the lesion laterality was not determined, as the left and right lesions were combined. Using a larger cohort (N = 90), Sihvonen et al. (2016, 2017a) followed stroke patients with left (N = 43) and right (N = 47) lesions from the acute to 6-month post-stroke stage. At the acute stage, AA was associated with a specific lesion pattern comprising right temporal [STG, middle temporal gyrus (MTG)] and subcortical (striatum, globus pallidus) regions as well as the right insula, IFG, and hippocampus (Fig. 2A). The lesion patterns for pitch-amusia and rhythm-amusia were largely overlapping, though lesions in the right dorsal striatum were the most significant in rhythm-amusia. In order to compare acute lesion patterns predicting later recovery of AA, the amusic group was further divided based on MBEA performance at the 3-month and 6-month stages, with patients scoring above the cut-off value of the MBEA (Peretz et al., 2003) defined as showing good recovery (recovered amusics) and patients scoring below the cut-off as showing poor recovery (non-recovered amusics). Lesions in the left IFG were associated with a better recovery of amusia whereas lesions in the right anterior STG, insula, and IFG were associated with a poor recovery (Fig. 2B). These results are similar to the VBM findings in CA (Hyde et al., 2006, 2007; Albouy et al., 2013) and suggest that the right STG and IFG are the core areas underlying severe, persistent AA. However, these results also indicate that damage to the left IFG may result in less severe, transient AA.

Interestingly, there was virtually no overlap between the lesion patterns of AA and aphasia, the latter being located in the left STG and insula (Sihvonen et al., 2016), supporting the dissociation of AA and aphasia found in earlier case studies (for a recent review, see Peretz and Coltheart, 2003). Nonetheless, around 45% of the amusic patients had at least minor aphasia (Sihvonen et al., 2016; Sihvonen, Ripollés et al., 2017a), similar to the percentages reported in earlier studies (Schuppert et al., 2000; Stewart et al., 2006), suggesting that musical and language deficits often occur together. In the healthy brain, speech and music share neural processing resources in auditory cortical and frontal regions (Koelsch and Siebel, 2005; Koelsch, 2011). However, as the two deficits can occur separately, it has been proposed that speech and music utilize overlapping neural resources but also have unique neural representations in the brain (Patel, 2003). Especially the IFG has been suggested to be a crucial node for the shared syntactic integration resources between music and speech (Patel, 2003) whereas their processing in non-primary temporal lobe areas shows regional selectivity, with speech being processed in more ventrolateral areas and music in more dorsomedial areas, extending into the inferior parietal lobule (IPL; Tervaniemi et al., 2006; Rogalsky et al., 2011; Norman-Haignere et al., 2015). The abovementioned VLSM results also provide some support for the shared resource hypothesis as they delineated lesions in the left IFG in association with transient AA (Sihvonen, Ripollés et al., 2017a).

There are, however, some notable methodological limitations to VLSM and to the causality and reliability of the conclusions that can be drawn from it. First of all, most VLSM studies lack pre-injury data on



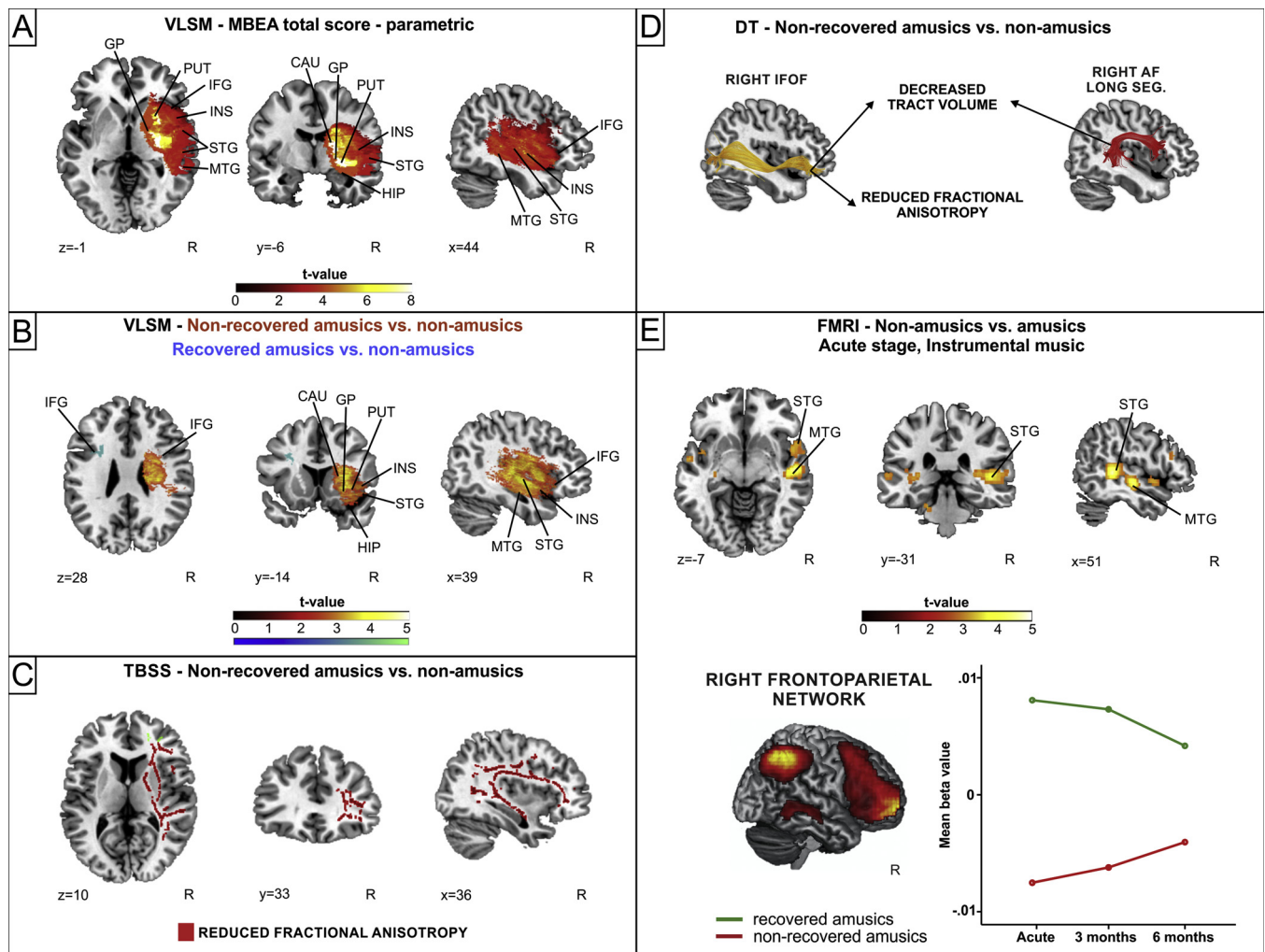
**Fig. 1.** Single case A) and group B) lesion studies regarding AA. The number of single cases / group studies which reported AA after damage to a particular brain region is shown for both spectral (left) and temporal (right) deficits. The same number is reported in different slices (for example, three case studies reported spectral deficits after damage to left frontal regions, so “3” is shown in the red ROI in both axial and sagittal slices). Areas in which no deficit was reported have no number. The different brain regions were identified using well-known atlases (Tzourio-Mazoyer et al., 2002; Frazier et al., 2005; Bürgel et al., 2006; Desikan et al., 2006; Makris et al., 2006; Goldstein et al., 2007; Wakana et al., 2007; Hua et al., 2008). Neurological convention is used with brain regions shown over a canonical template in MNI space. The figure is based on the data reported by Stewart et al. (2006; Supplementary Tables 1 & 2) and updated for studies from 2006 to 2018. See Supplementary Tables 1 and 2 for details. AA = Acquired amusia; MNI = Montreal Neurological Institution; ROI = Region of interest.

performance in the function or skill being assessed, often relying on self-report or other indirect indices to assess the premorbid level. Second, VLSM results do not take diaschisis into account and therefore do not assess the potential effects of functional changes outside the initial lesion site. Third, naturally occurring stroke lesions follow the vascular territories of the brain and therefore are not typically focal and restricted to one brain structure, but are generally larger and encompass multiple areas. Large lesions have been associated with poor outcomes in aphasia (Samson et al., 1999; Benganem et al., 2019), and a similar observation was made also in the recent AA studies, with larger lesion volumes in those amusics who did not show recovery over 6 months compared to those who did (Sihvonen et al., 2016; Sihvonen, Ripollés et al., 2017a). Importantly, given that larger lesions can disrupt

both local and more distant connections between brain areas (Catani and ffytche, 2005), VLSM results need to be integrated also with information on the integrity of white matter pathways.

## 2.2. Diffusion tensor imaging

Studies utilizing DTI in AA were lacking until 2016, when a subsample of the patients (N = 42) of the study by Sihvonen et al. (2016) was used to determine white matter pathway deficits underlying AA (Sihvonen, Ripollés et al., 2017b). Converging results from deterministic tractography (tract level) and tract-based spatial statistics (voxel level) analyses of acute stage DTI data showed that non-recovered amusic patients had reduced volume or fractional anisotropy (FA) in



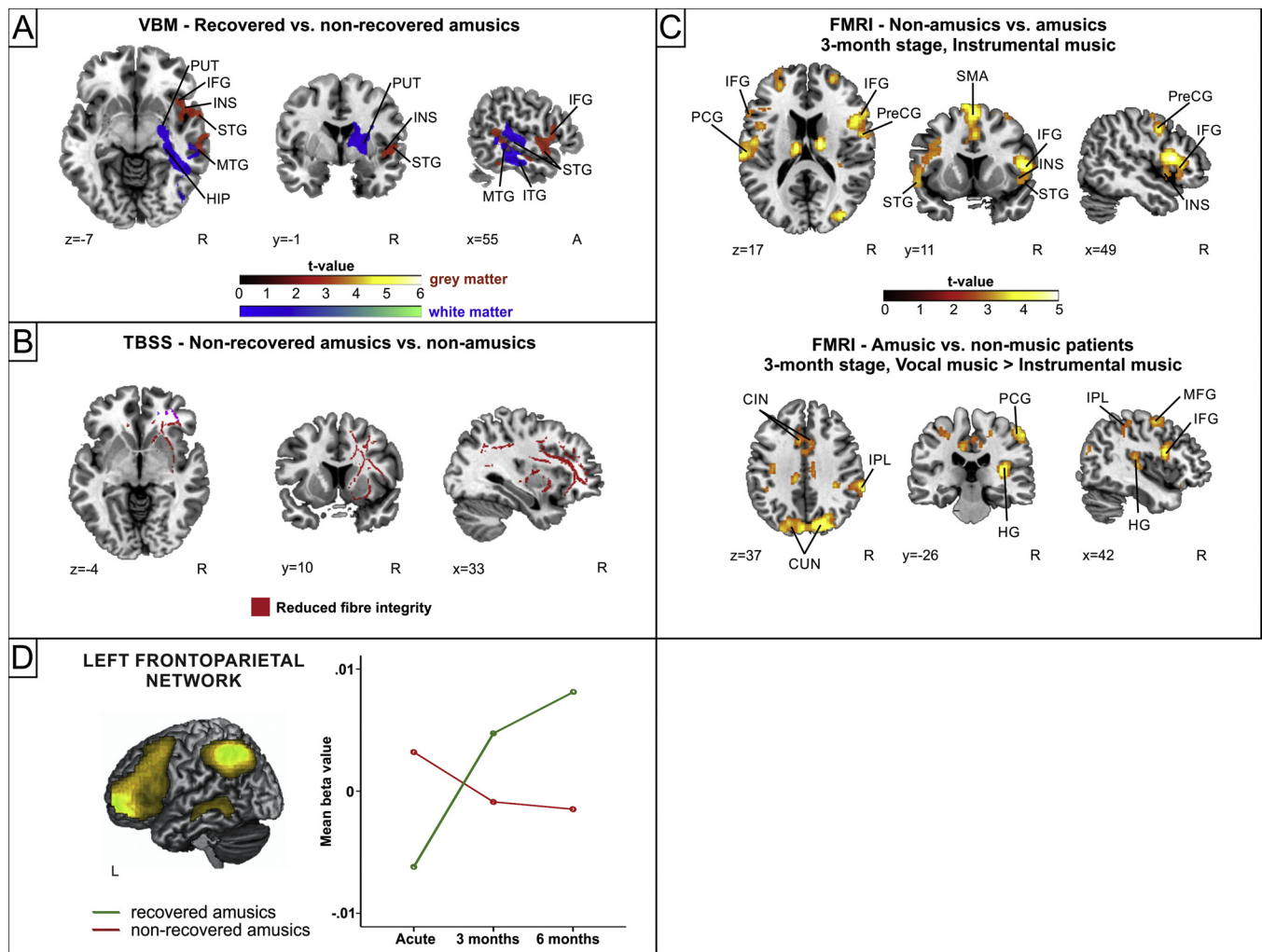
**Fig. 2.** Acute changes in AA. A) Stroke lesion pattern associated with lower MBEA total scores ( $N = 90$ ); B) VLSM analyses comparing non-recovered amusic vs. non-amusic patients (red;  $N = 74$ ), and recovered amusic vs. non-amusic patients (blue;  $N = 53$ ); C) TBSS analysis comparing non-recovered amusic vs. non-amusic patients ( $N = 42$ ); D) Main DT findings in AA at the acute stage ( $N = 42$ ); E) fMRI activation pattern comparison between the non-amusic and amusic patients during instrumental music listening at the acute stage ( $N = 41$ ), and right frontoparietal network functional connectivity engagement comparison between recovered and non-recovered amusic patients ( $N = 24$ ). CAU = Caudate; DT = Deterministic tractography; GP = Globus pallidus; HIP = Hippocampus; INS = Insula; PUT = Putamen; R = Right.

the right AF (long segment), inferior fronto-occipital fasciculus (IFOF), and uncinata fasciculus (UF), as well as in the corpus callosum (CC) compared to the non-amusics (Fig. 2C-D). In contrast, volume of the left AF (posterior segment) was associated with recovery of amusia. Importantly, all these effects emerged after controlling for potential confounding factors, including education, lesion size, and verbal memory performance, increasing their specificity for musical deficits. Overall, the recent DTI results in AA converge with the right dorsal stream deficit observed in CA (Loui et al., 2009), but also implicate other (i.e. ventral) right frontotemporal tracts (IFOF, UF) as well as interhemispheric tracts (CC) in severe and persistent AA. These findings in amusia parallel with recent findings on aphasia indicating that not only the left dorsal (AF) but also left ventral tracts (IFOF, UF) underlie deficits in speech processing, especially language comprehension (Kummerer et al., 2013; Harvey et al., 2013; Ivanova et al., 2016).

### 2.3. Functional magnetic resonance imaging

Using fMRI in stroke patients ( $N = 41$ ), Sihvonen and colleagues also explored changes in activation patterns and functional connectivity in AA during passive listening to vocal (sung) and instrumental versions of familiar songs (Sihvonen et al., 2017d). Music excerpts were

presented using a block-design with six blocks of vocal music, six blocks of instrumental music and 12 blocks of rest (no-stimuli) in between the music blocks. The duration of each block was 15 s. At the acute post-stroke stage, amusic patients showed clearly reduced activation to instrumental music in the right STG/MTG compared to non-amusics (Fig. 2E). Functional connectivity analyses indicated that the amusics with poor recovery showed reduced engagement of the right frontoparietal network compared to amusics with good recovery, suggesting impaired allocation of attention to instrumental music, already at the acute stage. Interestingly, amusics did not show decreased activations or functional connectivity deficits in the vocal music condition. In fact, compared to non-amusics, the amusics showed enhanced activation in right frontal [IFG; middle frontal gyrus (MFG)], temporal (Heschl's gyrus, HG), and parietal [IPL, post central gyrus (PCG)] areas, the left supplementary motor area (SMA), and bilateral medial parieto-occipital (cuneus, precuneus) and frontal (anterior cingulate) areas to vocal vs. instrumental music at the 3-month stage (Fig. 3C). As there were no significant differences between the non-amusic and amusic groups or amusics with good or poor recovery in aphasia occurrence (Sihvonen et al., 2017d), this effect of preserved vocal music processing in AA is unlikely to be explained by post-stroke aphasia.



**Fig. 3.** Longitudinal changes in AA. A) Grey (red) and white matter (blue) VBM analyses comparing recovered and non-recovered amusic patients (N = 53); B) TBSS analysis comparing non-recovered amusic vs. non-amusic patients (N = 25); C) fMRI activation pattern comparison between the non-amusic and amusic patients during instrumental music listening and amusic vs. non-music patients during vocal music > instrumental music listening at the 3-month stage (N = 41); D) Left frontoparietal network functional connectivity engagement comparison between recovered and non-recovered amusic patients (N = 24). CIN = Cingulate gyrus; CUN = Cuneus; HG = Heschl's gyrus; HIP = Hippocampus; INS = Insula; IPL = Inferior parietal lobule; L = Left; MFG = Middle frontal gyrus; PCG = Postcentral gyrus; PUT = Putamen; R = Right.

### 3. Longitudinal neural changes underlying the recovery of acquired amusia

#### 3.1. Voxel-based morphometry

Sihvonen and colleagues utilized VBM in stroke patients (N = 90) to explore GMV and white matter volume (WMV) changes associated with the longitudinal (acute to 6-month post-stroke stage) outcome of AA (Sihvonen et al., 2016; Sihvonen, Ripollés et al., 2017a). While controlling for education and lesion size, poor vs. good amusia recovery was associated with GMV decrease in the right STG/MTG and IFG, and with WMV decrease in the right MTG, inferior temporal gyrus (ITG), striatum, and hippocampus (Fig. 3A), indicating that impaired amusia recovery is associated with atrophy in areas adjacent to the initial lesion. This atrophy pattern was somewhat different depending on amusia type: poor recovery was linked to right posterior STG/MTG and IPL atrophy in pitch-amusia and to right anterior MTG/ITG and hippocampus atrophy in rhythm-amusia. The anterior-posterior distribution of the rhythm- and pitch-amusia atrophy patterns along the temporal plane is similar to the findings reported in both animals (Bendor and Wang, 2008) and humans (Warren et al., 2005; Jamison et al., 2006; Samson et al., 2011) where anterior temporal regions show

greater sensitivity to changes in the temporal domain and posterior temporal regions show great sensitivity to changes in the spectral domain. In addition to the right posterior STG/MTG, the right IPL has an important role in melodic perception, especially in maintaining tonal pitch structure in working memory (Royal et al., 2016).

#### 3.2. Diffusion tensor imaging

The longitudinal DTI data linked persistent amusia to a progressive white matter damage, indicated by increased mean or radial diffusivity (MD/RD), in the right IFOF, AF, and UF as well as in the CC (Fig. 3B; Sihvonen, Ripollés et al., 2017b). This degenerative pattern was similar in rhythm- and pitch-amusia for the right frontotemporal tracts (IFOF, AF, UF), but there were also some differences. In rhythm-amusia, poor recovery was additionally associated with MD/RD increase in the left AF. In pitch-amusia, MD/RD increase in the posterior part of the CC, which connects the left and right temporal lobes, was linked to poor recovery whereas MD/RD decrease in the right anterior AF was linked to good recovery, suggesting that preservation of this dorsal tract connecting the right IFG and IPL plays a role in the recovery of pitch-amusia. Interestingly, and in contrast with the deficient dorsal tract thought to underlie CA, the ventral tract (IFOF) deficiency was the

strongest predictor of AA in two regression analyses.

### 3.3. Functional magnetic resonance imaging

Longitudinal fMRI data showed that in the instrumental music condition, good vs. poor amusia recovery was linked to increased activation in left and right MFG and IPL, left superior parietal lobule (SPL), and right precentral gyrus (PreCG) at the 3-month stage and in right IFG and MFG at the 6-month stage as well as to increased functional connectivity in the left frontoparietal network, especially during the first 3 months (Fig. 3C-D; Sihvonen et al., 2017d). Lesion size did not differ between the recovered and non-recovered amusics. These results suggest that amusia recovery is underpinned by a dynamic shift characterized by a widespread recruitment of bilateral frontoparietal regions at the early stage and more focal right prefrontal regions at later stage. This pattern was instrumental music specific as similar changes were not observed in the vocal condition, which also suggests that the observed effects cannot be due to deficits in general attentional orientation. In the vocal condition, increased bilateral cerebellar activation at 6 months was seen in the non-recovered compared to recovered amusics, potentially indicating that AA recovery is associated with less neural effort in the sensory-motor processing and possible covert motor articulation of singing (Callan et al., 2007; Brattico et al., 2011). Overall, the pattern of increased bilateral activation to music in AA recovery closely mirrors that of language recovery: aphasics who recover show an upregulation of bilateral frontal regions, especially IFG and SMA, at subacute stage, followed by normalization of activation with a re-shift to the left hemisphere in the chronic stage (Saur et al., 2006).

### 4. Towards a neural model of acquired amusia

Functional neuroimaging studies on healthy subjects have shown that music perception involves a wide-spread network comprising bilateral temporal, frontal, parietal, and subcortical brain regions (Schmithorst, 2005; Brattico et al., 2011; Alluri et al., 2012). Studies on stroke patients have provided similar evidence of cross-hemispheric network underlying music perception. However, as suggested first by Peretz (1990) and later by Schuppert and colleagues (2000), music perception relies on initial recognition of global musical structures in the right hemisphere, supported by the left hemisphere subsystems that are subordinate to the right hemisphere (Peretz, 1990; Schuppert et al., 2000). In rhythm perception for example, these different systems interpret metre (global) or discriminate the durational values of notes (local) to process the temporal information of auditory stimuli (Peretz, 1990). In general, spatially distributed brain areas subserving a cognitive function are connected through white matter tracts which form a network to maximize the processing, storage, and manipulation of information (Ross, 2010). Disruption of the neural network and its connections can lead to a disconnection syndrome and a cognitive-behavioural deficit (Catani and Mesulam, 2008; Thiebaut de Schotten et al., 2008). In musical domain, analysing musical structures demand various cognitive architectures which can be selectively impaired leading to a fine-grained forms of AA (Clark et al., 2015).

Based on the recent multimodal MRI results discussed above, which extend earlier symptom-led and lesion-led explorations of AA (Stewart et al., 2006) as well as provide a more precise, spatially accurate, and comprehensive picture of the structural and functional neural changes underpinning AA and its recovery, the critical connections for music perception seem to be located in the right hemisphere, in contrast with the bilateral large-scale music network observed in healthy subjects. The core of the lesion area causing AA is in the right insula and striatum from where the lesion extends to temporal (STG/MTG), frontal (IFG), and limbic (hippocampus) areas. This lesion area affects crucial frontotemporal pathways, especially the ventral stream, but also the dorsal pathway, linking the right temporal and inferior frontal regions, thus

leading to AA. From ontogenetic and phylogenetic standpoints, the results linking the right IFOF to music perception is particularly interesting since in humans, the IFOF is known to be present already at birth (Perani et al., 2011), but it is clearly less developed in monkeys (Thiebaut de Schotten et al., 2012). While the prime neural architectures in AA were right-lateralised, amusia was also associated with damage to interhemispheric connectivity (i.e. the CC and tapetum), more pronouncedly in rhythm-amusia (Sihvonen, Ripollés et al., 2017b). In contrast, damage to left frontal areas (IFG) or left temporo-parietal pathways were associated with better later recovery (i.e. transient AA). Moreover, the lesion pattern in AA functionally inhibits the engagement of the right STG/MTG in music listening (Sihvonen et al., 2017d). Altogether, these findings support the rationale of additional left hemispheric subsystems needed in music perception and processing, although with right hemisphere dominance.

The longitudinal recovery process of AA is driven by a complex set of both structural and functional neural changes. Impaired recovery of AA was associated with atrophy in the right cortical (STG, MTG, ITG, IFG) and subcortical (striatum, hippocampus) areas adjacent to the lesion as well as degeneration of the right frontotemporal tracts (IFOF, AF, UF), the left AF (in rhythm-amusics), and the posterior CC (in pitch-amusics). Poor recovery of amusia was associated with large lesion size and predicted by the extent of damage to the right frontotemporal pathways (mainly ventral). In addition, the amusics who did not recover over the following 6 months had reduced functional connectivity in the right frontoparietal network at the acute stage compared to the recovered amusics. In contrast, good recovery of AA was promoted by increased recruitment of both left and right dorsal streams as well as the interhemispheric pathways. Amusia recovery was also facilitated by preservation of the right anterior AF (in pitch-amusia) as well as increased functional recruitment of largely bilateral frontal (IFG, MFG, PreCG) and parietal (IPL, SPL) regions and the left frontoparietal network.

In language research, two processing streams, dorsal and ventral, are broadly accepted to underlie speech processing (Rauschecker and Tian, 2000; Hickok and Poeppel, 2007; Rauschecker, 2014). The language dual-stream model is largely left dominant, but, for example, spectrotemporal analysis and phonological processing are thought to be largely bilateral, and overall the model assumes that the ventral stream is largely bilaterally organized (Hickok and Poeppel, 2007). A similar dual-stream model has been proposed to act in parallel in music processing, transferring crucial musical auditory information between the temporal, inferior parietal, and inferior frontal regions in the right hemisphere (Zatorre et al., 2002; Rauschecker, 2014; Sammler et al., 2015; Loui, 2015; Musso et al., 2015). Of the two streams, the dorsal stream (“where” or “how”) connecting temporal and inferior parietal regions with frontal areas is hypothesized to be important for evaluation of audio-motor movement and spatial information, whereas the ventral stream (“what”) connecting parieto-occipital, temporal and inferior frontal areas is involved in categorizing sound to auditory objects, pitch class and melodic contour (Rauschecker and Tian, 2000; Griffiths et al., 2007; Rauschecker and Scott, 2009; Rauschecker, 2014; Sammler et al., 2015). In aphasia, damage to the dorsal stream is associated with productive impairments, while comprehension deficits are associated with injury of the ventral stream (extreme capsule, or rather the IFOF; Kummerer et al., 2013). In the musical domain, it is likewise possible that damage to individual pathways (dorsal or ventral) would manifest in different musical impairments (production versus perception; Loui et al., 2008; Loui, 2015; Sammler et al., 2015). If both the ventral and dorsal streams are damaged, due to larger lesion size or location, it is unlikely that AA recovers. Instead, acquired amusics with at least one preserved right hemispheric music-related pathway interconnecting frontal, parietal and temporal regions could engage recovery as the two streams have been found to share functionalities and mediate compensatory mechanisms in the language domain (Lopez-Barroso et al., 2011). This rationale is supported by the

recent results (Sihvonen et al., 2017a, 2017b).

While the structural findings in AA were largely right-lateralised, functional anomalies were observed in both hemispheres during instrumental music listening. In addition to the global (i.e. metre) versus local (i.e. rhythm) dissociation of auditory information processing discussed previously (Peretz, 1990; Schuppert et al., 2000), an additional explanation is that the critical hubs, meaning brain areas crucial for enabling neuronal signalling and communication (van den Heuvel and Sporns, 2013), in the music processing network are located in the right hemisphere (Schmithorst, 2005; Brattico et al., 2011; Alluri et al., 2012) and damage to these neural structures manifests in wide-spread processing deficits during music perception. Collectively, the previously published studies suggest that these critical hubs are the right STG/MTG and IFG, and moreover comprise the white matter pathways interconnecting the two regions, similar to CA (Peretz, 2016). However, the critical connection damaged in AA seems to be the right ventral stream as opposed to the dorsal stream. As AA can occur also after left hemisphere damage (Schuppert et al., 2000) lesions affecting the crucial tracts interconnecting music processing areas in the left hemisphere to the crucial right hemispheric music-related brain regions (i.e. critical hubs) might lead to AA. Moreover, intact right hemisphere has been suggested to compensate for the music perception deficits after left hemisphere damage (Schuppert et al., 2000) which underlines the importance of the right hemisphere in music processing. One other possible explanation is that during naturalistic music listening, more global auditory information processing is needed, in contrast to local processing (Peretz, 1990; Schuppert et al., 2000).

Moreover, the disparity between the lateralisation of lesion and functional anomalies could arise from stimulus complexity. In language domain, the lateralisation of prosodic emotion processing is dependent on the verbal complexity: As the complexity of the presented prosodic information increases from sentences with asyllabic to monosyllabic and to multi-syllable words, the fMRI patterns shifts from being predominantly right-lateralized to bilateral activity (Mitchell and Ross, 2008). Similarly, music contains complex acoustic components as well as a language component, and therefore it is reasonable to expect bilateral wide-spread brain activations during music listening (Toiviainen et al., 2014) than during listening to single tones or melodies (Hyde et al., 2008; Jerde et al., 2011). Taken together, right hemisphere lesions leading to AA might manifest in wide-spread global music processing deficits whereas left hemisphere damage might affect only local processing and thus lead to small-scale activation deficits.

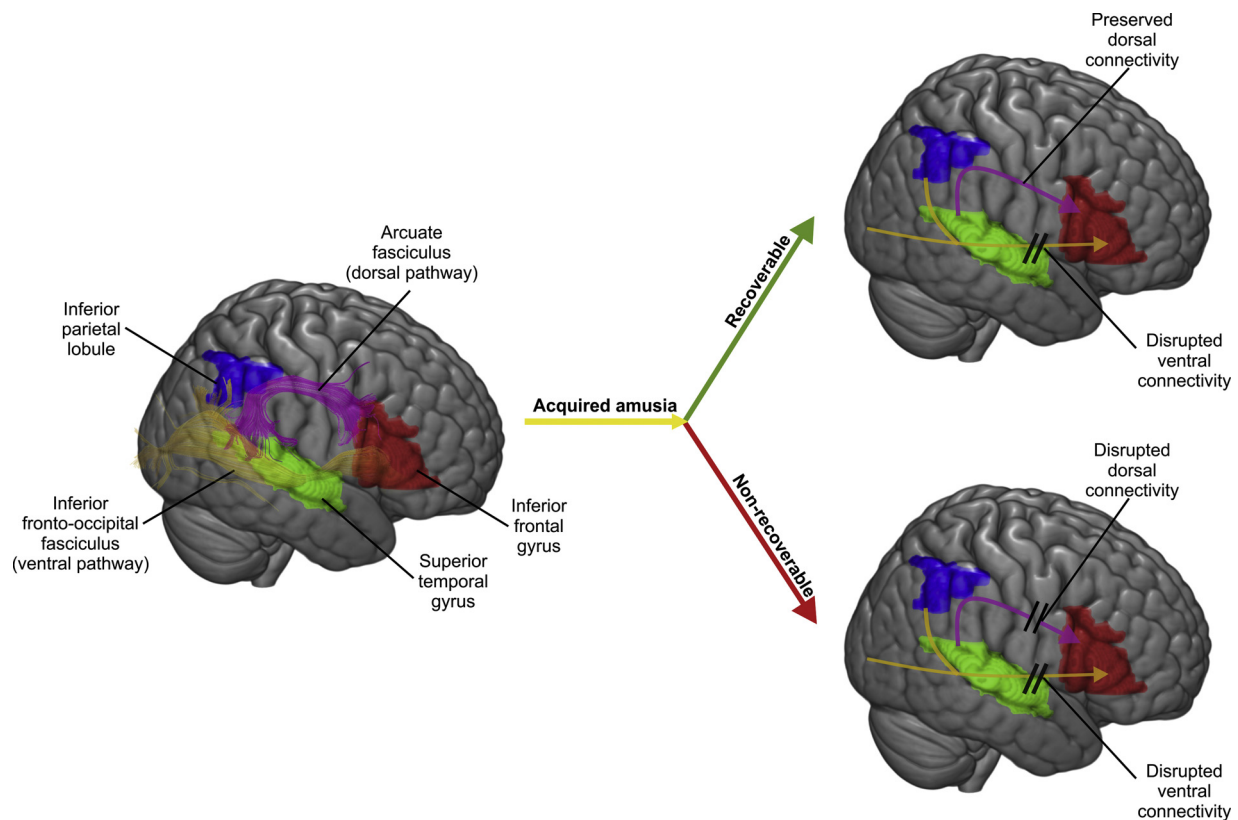
Music with vocals combines characteristics of both language (e.g. linguistic syntax, semantics) and music (e.g. melody, harmony, rhythm). Interestingly, amusics showed enhanced activation to vocal vs. instrumental music in an extensive network of right temporal (HG) and frontoparietal (IFG, MFG, IPL, PCG) cortical areas, left SMA, and medial frontoparietal (e.g., cingulate, precuneus) areas (Sihvonen et al., 2017d). This suggests that the processing of the vocal component of music is relatively well preserved in AA and mediated by spared auditory, vocal-motor, and attention- and memory-related regions, similar to those being reported in fMRI studies of healthy subjects comparing vocal and instrumental music processing (Brattico et al., 2011; Alluri et al., 2013; Lévêque and Schön, 2015). Moreover, as there were no significant differences between the groups in the occurrence of post-stroke aphasia, the observed results are unlikely to be explained by dissimilarities in language processing between the amusic and non-amusic patients. However, this finding is based on one study and it therefore needs to be replicated and further studied in the future for more details.

Overall, neuroimaging studies on healthy subjects have shown that the processing of music and speech share resources in the brain, but preferentially engage distinct cortical networks: listening to music activates the insula and superior temporal regions bilaterally as well as the right IFG more than listening to speech (LaCroix et al., 2015). Similarly, both shared and distinct neural networks facilitate singing and

speaking. Both functions engage a large network including sensorimotor areas and inferior frontal regions, but compared to speaking, singing induces greater activations in the right temporoparietal regions as well as in right frontal regions (Callan et al., 2006; Özdemir et al., 2006). The recent AA studies provide evidence on both shared and distinct resources underlying music and language processing in the brain. Post-stroke language and musical deficits can often occur together (Sihvonen et al., 2016; Sihvonen, Ripollés et al., 2017a), yet these domains can be selectively impaired (Sidtis and Volpe, 1988; Peretz et al., 1997; Tzortzis et al., 2000; Piccirilli et al., 2000; Mendez, 2001; Uetsuki et al., 2016). The lesion patterns giving rise to aphasia and persistent AA showed clear lateralization (Sihvonen et al., 2016), clustering in left and right hemispheres, respectively. In contrast, the stroke lesions associated with recoverable AA were localized primarily in the left IFG, a crucial node of shared resources between music and speech (Patel, 2003). In AA, the right ventral and dorsal streams were the most critically damaged white matter pathways, with the degree of initial damage to the right ventral stream being the most significant predictor of severe AA (Sihvonen, Ripollés et al., 2017b). As the right ventral stream is implicated in both language (Hickok and Poeppel, 2007) and music processing (Sihvonen, Ripollés et al., 2017b), based on the recent results, this suggests that this crucial pathway is a part of the shared neural network between these two domains with a role especially in the encoding and analysis melodic features important for music and speech perception. In contrast, the processing of syntactic information in music and language have been shown to share a left hemispheric network centred upon left IFG and on left dorsal and ventral pathways (Musso et al., 2015). Interestingly, and in contrast with syntactic processing, the perception of prosody relies on both dorsal and ventral pathways in the right hemisphere (Wildgruber et al., 2006; Sammler et al., 2015; Frühholz et al., 2015). While post-stroke aprosodia has also been linked to right hemisphere damage (Ross and Monnot, 2008; Ross, 2010; Jafari et al., 2017), recent evidence suggests a cross-talk between the hemispheres via the posterior corpus callosum (i.e. tapetum) is needed to combine prosodic and syntactic information in language (Sammler et al., 2018). These posterior transcallosal fibers were also implicated in AA, especially in pitch-amusia (Sihvonen, Ripollés et al., 2017b), and similar to language processing, it is possible that the pitch information in music is transferred to the left hemisphere for syntactic integration via this pathway, as music-syntactic processing has been shown to engage the IFG bilaterally, but with right-hemispheric weighting (Maess et al., 2001; Koelsch and Siebel, 2005; Tillmann et al., 2006). Overall, acting in conjunction, the two streams transform complex acoustic feature combinations into abstract representations and analyse sensorimotor information to be integrated with these representations (Rauschecker and Scott, 2009). The discussed data suggest that normal music perception relies on this dual route, especially in the right hemisphere. Crucially, the recent results enable modelling the cascade of lesion-induced structural changes giving rise to AA (Sihvonen et al., 2016; Hirel et al., 2017; Sihvonen, Ripollés et al., 2017a) and the structural (Sihvonen et al., 2016; Sihvonen, Ripollés et al., 2017a, b) and functional (Sihvonen et al., 2017d) changes that either impair or facilitate recovery from AA (Fig. 4).

## 5. Conclusions, clinical considerations and future directions

While AA is a common deficit after a middle cerebral artery stroke, with prevalence ranging between 35% and 69% (Ayotte et al., 2000; Schuppert et al., 2000; Särkämö et al., 2009), it is not routinely evaluated in clinical practice and therefore remains underdiagnosed. The novel findings reported in this review enable an accurate identification of AA, based on recognition of amusia lesion pattern reported by VLSM studies and whether it damages the ventral or dorsal streams or both in the right hemisphere, and subsequent evaluation of the patient's music abilities (i.e. perception and production) using, for example, the MBEA



**Fig. 4.** Dual-stream model of acquired amusia. Both the right ventral and the dorsal stream play an important role in amusia recovery, and if both ventral and dorsal streams in the right hemisphere are damaged, recovery from acquired amusia is unlikely. However, if one of these streams in the right hemisphere is preserved, recovery is possible due to the shared functionalities of the streams.

(Peretz et al., 2003) as a screening test for amusia. The results cited here also provide a prognostic tool for AA outcome: initially amusic patients with smaller lesions and preserved dorsal stream are more likely to recover. While the current studies focused on cognitive (pitch and rhythm processing) aspects of music, the hedonic qualities of music should not be neglected as patients with right hemisphere damage have shown to have impaired emotional, rewarding, vegetative and sentimental aspects of music (Behne, 1997). In healthy subjects, musical anhedonia has been associated mainly with selective reduction of activity in the nucleus accumbens, as well as its decreased functional and structural connectivity to the right auditory cortex (Martinez-Molina et al., 2016; Hernandez et al., 2019; Martinez-Molina et al., 2019). The first case describing acquired musical anhedonia was reported over 25 years ago (Mazzoni et al., 1993). This patient with a right temporoparietal lesion was observed to have lost the capacity to evaluate qualitative aspects of music experiences, and specially the emotional involvement of music, in spite of performing normally in all cognitive domains (see also following case reports of musical anhedonia after brain lesions Griffiths et al., 2004; Satoh et al., 2011, 2016). Belfi et al. (2017) investigated a large group of patients with focal brain damage with the Musical Anhedonia Questionnaire and the Barcelona Music Reward Questionnaire (Mas-Herrero et al., 2013) to assess whether the ability to feel musical enjoyment and reward is impaired after brain injury (Belfi et al., 2017). However, no pattern of brain lesions emerged that could reliably predict musical anhedonia. Overall, musical anhedonia was rare among the patients, suggesting that musical reward may be highly resistant to neural damage or that damage in several parts on the auditory-reward decoding network might induce similar deficits (Loui et al., 2017; Martinez-Molina et al., 2019). Some authors have reported cases in which the loss of aesthetic pleasure was concurrent with AA (Mazzucchi et al., 1982; Hirel et al., 2014). In this regard, a recent study has shown that while subjects with CA showed impairment

in a music emotional recognition task, the intensity of the emotional experience of music was intact when compared to a matched control sample (Leveque et al., 2018). This study highlights the importance of further studying the impact of amusia in emotional processing, as for example the possible dissociation between emotional recognition and emotional impact.

Given the quintessential role of music in human life, diagnosing AA is especially important in patients who are vocationally engaged with music, such as musicians and music teachers, but also in those patients who have musical hobbies or for whom music-based rehabilitation is considered (Sihvonen et al., 2017b). Based on the recent fMRI study on AA (Sihvonen et al., 2017d), if music-based interventions are considered for amusic patients, vocal music listening and singing-based intervention could be promising as vocal music processing seems to be, at least partly, preserved in amusic brain. More particularly, if AA is accompanied with aphasia, Melodic Intonation Therapy (MIT; Albert et al., 1973) might still be a viable method of language rehabilitation as the processing of vocal aspects in music are preserved (Sihvonen et al., 2017d). However, as the proposed pathway to language recovery using MIT is through recruitment of homologous language and speech-motor regions in the right hemisphere (Schlaug et al., 2010) utilizing the right dorsal stream (Schlaug et al., 2009; Wan et al., 2014), the gains obtained through MIT are likely to be dependent on the preservation of the right dorsal stream. Amusia is often coupled also with problems in linguistic (Liu et al., 2010) or emotional (Thompson et al., 2012; Jafari et al., 2017) prosody, which rely on the perception subtle pitch, timbre, and intensity variations in speech. This may lead to difficulties in everyday communication and social interaction. While intervention studies on AA are lacking, singing interventions have been found promising in CA (Anderson et al., 2012; Wilbiks et al., 2016) and in light of the preserved vocal music processing observed with fMRI in AA (Sihvonen et al., 2017d) could provide a tool also in the rehabilitation



of AA.

As a whole, music processing entails multiple elements, ranging from the perceptual analysis of different musical components, including tonality, melodic intervals and contours, rhythm, and meter, to productive elements, such as singing and moving to music, the impairment of which can give rise to a spectrum of more fine-grained forms of AA (Peretz and Coltheart, 2003). Although most recent studies discussed above have utilized only MBEA in testing specific musical abilities (i.e. pitch and rhythm perception), their results have revealed functionally crucial neural components of the music network. In future, further research on both perceptual and productive musical deficits is needed to determine in depth how the music processing structures function at network level. This would be promoted by studying AA that stems from various neurological diseases with different symptoms, neural bases and trajectories. Although this review focuses on the recent advances in understanding stroke-induced amusia, studying musical abilities in persons with dementia is encouraged as these patients have been shown to have pitch processing deficits compared to healthy age-matched controls, while the function of various other musical modules (e.g. temporal and timbre processing) remain intact (Golden et al., 2017). Moreover, studying music processing, both intact and defective, across different musical cultures would provide information on universally shared musical neural structures. Methodologically, precise modelling of structural and functional connections of the individual musical modules is needed, which requires improved MRI methods, comprehensive testing of the subjects' musical abilities as well as larger sample sizes and even combination of data sets. In addition, longitudinal analyses of lesion sizes and their relation to AA recovery are needed. Application of state-of-the-art multivoxel pattern analysis to the VLSM (Sperber et al., 2018) and functional data (Zavaglia et al., 2015) obtained from patients with AA would provide even more precise view of the essential neural structures involved in music perception.

## Funding

Financial support for the work was provided by the Academy of Finland (grants 257077, 277693, 299044), Tyks Research Funding (grant 13944), Finnish Brain Research and Rehabilitation Foundation, Finnish Brain Foundation, Finnish Cultural Foundation, Ella and Georg Ehrnrooth Foundation, Signe and Ane Gyllenberg Foundation, Maire Taponen Foundation, and Jenny and Antti Wihuri Foundation.

## Appendix A. Supplementary data

Supplementary material related to this article can be found, in the online version, at doi:<https://doi.org/10.1016/j.neubiorev.2019.08.023>.

## References

Adolphs, R., 2016. Human lesion studies in the 21st century. *Neuron* 90, 1151–1153.

Albert, M.L., Sparks, R.W., Helm, N.A., 1973. Melodic intonation therapy for aphasia. *Arch. Neurol.* 29, 130–131.

Albouy, P., Mattout, J., Sanchez, G., Tillmann, B., Caclin, A., 2015. Altered retrieval of melodic information in congenital amusia: insights from dynamic causal modeling of MEG data. *Front. Hum. Neurosci.* 9, 20.

Albouy, P., Peretz, I., Bermudez, P., Zatorre, R.J., Tillmann, B., Caclin, A., 2019. Specialized neural dynamics for verbal and tonal memory: fMRI evidence in congenital amusia. *Hum. Brain Mapp.* 40, 855–867.

Albouy, P., Mattout, J., Bouet, R., Maby, E., Sanchez, G., Aguera, P.E., et al., 2013. Impaired pitch perception and memory in congenital amusia: the deficit starts in the auditory cortex. *Brain* 136, 1639–1661.

Alluri, V., Toivainen, P., Jääskeläinen, I.P., Glerean, E., Sams, M., Brattico, E., 2012. Large-scale brain networks emerge from dynamic processing of musical timbre, key and rhythm. *Neuroimage* 59, 3677–3689.

Alluri, V., Toivainen, P., Lund, T.E., Wallentin, M., Vuust, P., Nandi, A.K., et al., 2013. From Vivaldi to Beatles and back: predicting lateralized brain responses to music. *Neuroimage* 83, 627–636.

Anderson, S., Himonides, E., Wise, K., Welch, G., Stewart, L., 2012. Is there potential for learning in amusia? A study of the effect of singing intervention in congenital amusia.

Ann. N. Y. Acad. Sci. 1252, 345–353.

Ayotte, J., Peretz, I., Rousseau, I., Bard, C., Bojanowski, M., 2000. Patterns of music agnosia associated with middle cerebral artery infarcts. *Brain* 123, 1926–1938.

Bates, E., Wilson, S.M., Saygin, A.P., Dick, F., Sereno, M.I., Knight, R.T., et al., 2003. Voxel-based lesion-symptom mapping. *Nat. Neurosci.* 6, 448–450.

Behne, K., 1997. The development of "musikerleben" in adolescence: how and why young people listen to music. In: Deliège, I., Sloboda, J. (Eds.), *Perception and Cognition of Music*. Hove. Psychology Press/Erlbaum (UK) Taylor & Francis, England, pp. 143–159.

Belfi, A.M., Evans, E., Heskje, J., Bruss, J., Tranel, D., 2017. Musical anhedonia after focal brain damage. *Neuropsychologia* 97, 29–37.

Bendor, D., Wang, X., 2008. Neural response properties of primary, rostral, and rostrotemporal core fields in the auditory cortex of marmoset monkeys. *J. Neurophysiol.* 100, 888–906.

Benghanem, S., Rosso, C., Arbizu, C., Moulton, E., Dormont, D., Leger, A., et al., 2019. Aphasia outcome: the interactions between initial severity, lesion size and location. *J. Neurol.* 266, 1303–1309.

Brattico, E., Alluri, V., Bogert, B., Jacobsen, T., Vartiainen, N., Nieminen, S., et al., 2011. A functional MRI study of happy and sad emotions in music with and without lyrics. *Front. Psychol.* 2, 308.

Bürgel, U., Amunts, K., Hoemke, L., Mohlberg, H., Gilsbach, J.M., Zilles, K., 2006. White matter fiber tracts of the human brain: three-dimensional mapping at microscopic resolution, topography and intersubject variability. *Neuroimage* 29, 1092–1105.

Callan, D.E., Kawato, M., Parsons, L., Turner, R., 2007. Speech and song: the role of the cerebellum. *Cerebellum* 6, 321–327.

Callan, D.E., Tsytarev, V., Hanakawa, T., Callan, A.M., Katsuhara, M., Fukuyama, H., et al., 2006. Song and speech: brain regions involved with perception and covert production. *Neuroimage* 31, 1327–1342.

Catani, M., Mesulam, M., 2008. The arcuate fasciculus and the disconnection theme in language and aphasia: history and current state. *Cortex* 44, 953–961.

Catani, M., fytche, D.H., 2005. The rises and falls of disconnection syndromes. *Brain* 128, 2224–2239.

Chen, J.L., Kumar, S., Williamson, V.J., Scholz, J., Griffiths, T.D., Stewart, L., 2015. Detection of the arcuate fasciculus in congenital amusia depends on the tractography algorithm. *Front. Psychol.* 6, 9.

Clark, C.N., Golden, H.L., Warren, J.D., 2015. Acquired amusia. *Handb. Clin. Neurol.* 129, 607–631.

Desikan, R.S., Segonne, F., Fischl, B., Quinn, B.T., Dickerson, B.C., Blacker, D., et al., 2006. An automated labeling system for subdividing the human cerebral cortex on MRI scans into gyral based regions of interest. *Neuroimage* 31, 968–980.

Dronkers, N.F., Wilkins, D.P., Van Valin Jr, R.D., Redfern, B.B., Jaeger, J.J., 2004. Lesion analysis of the brain areas involved in language comprehension. *Cognition* 92, 145–177.

Frazier, J.A., Chiu, S., Breeze, J.L., Makris, N., Lange, N., Kennedy, D.N., et al., 2005. Structural brain magnetic resonance imaging of limbic and thalamic volumes in pediatric bipolar disorder. *Am. J. Psychiatry* 162, 1256–1265.

Freitas, C., Manzano, E., Burini, A., Taylor, M.J., Lerch, J.P., Anagnostou, E., 2018. Neural correlates of familiarity in music listening: a systematic review and a neuroimaging meta-analysis. *Front. Neurosci.* 12, 686.

Frühholz, S., Gschwind, M., Grandjean, D., 2015. Bilateral dorsal and ventral fiber pathways for the processing of affective prosody identified by probabilistic fiber tracking. *Neuroimage* 109, 27–34.

Geva, S., Baron, J.C., Jones, P.S., Price, C.J., Warburton, E.A., 2012. A comparison of VLSM and VBM in a cohort of patients with post-stroke aphasia. *Neuroimage Clin.* 1, 37–47.

Golden, H.L., Clark, C.N., Nicholas, J.M., Cohen, M.H., Slattery, C.F., Paterson, R.W., et al., 2017. Music perception in dementia. *J. Alzheimers Dis.* 55, 933–949.

Goldstein, J.M., Seidman, L.J., Makris, N., Ahern, T., O'Brien, L.M., Caviness Jr, V.S., et al., 2007. Hypothalamic abnormalities in schizophrenia: sex effects and genetic vulnerability. *Biol. Psychiatry* 61, 935–945.

Gordon, C.L., Cobb, P.R., Balasubramaniam, R., 2018. Recruitment of the motor system during music listening: an ALE meta-analysis of fMRI data. *PLoS One* 13, e0207213.

Graziano, A.B., Johnson, J.K., 2015. Music, neurology, and psychology in the nineteenth century. *Prog. Brain Res.* 216, 33–49.

Griffiths, T.D., Warren, J.D., Dean, J.L., Howard, D., 2004. "When the feeling's gone": a selective loss of musical emotion. *J. Neurol Neurosurg Psychiatry* 75, 344–345.

Griffiths, T.D., Kumar, S., Warren, J.D., Stewart, L., Stephan, K.E., Friston, K.J., 2007. Approaches to the cortical analysis of auditory objects. *Hear. Res.* 229, 46–53.

Harvey, D.Y., Wei, T., Ellmore, T.M., Hamilton, A.C., Schnur, T.T., 2013. Neuropsychological evidence for the functional role of the uncinate fasciculus in semantic control. *Neuropsychologia* 51, 789–801.

Hernandez, M., Palomar-García, M.A., Nohales-Nieto, B., Olcina-Sempere, G., Villar-Rodríguez, E., Pastor, R., et al., 2019. Separate contribution of striatum volume and pitch discrimination to individual differences in music reward. *Psychol. Sci.*, 956797619859339.

Hickok, G., Poeppel, D., 2007. The cortical organization of speech processing. *Nat. Rev. Neurosci.* 8, 393–402.

Hirel, C., Nighoghossian, N., Leveque, Y., Hannoun, S., Fornoni, L., Daligault, S., et al., 2017. Verbal and musical short-term memory: variety of auditory disorders after stroke. *Brain Cogn.* 113, 10–22.

Hirel, C., Leveque, Y., Deiana, G., Richard, N., Cho, T.H., Mechtouff, L., et al., 2014. Acquired amusia and musical anhedonia. *Rev. Neurol. (Paris)* 170, 536–540.

Hua, K., Zhang, J., Wakana, S., Jiang, H., Li, X., Reich, D.S., et al., 2008. Tract probability maps in stereotaxic spaces: analyses of white matter anatomy and tract-specific quantification. *Neuroimage* 39, 336–347.

Hyde, K.L., Zatorre, R.J., Peretz, I., 2011. Functional MRI evidence of an abnormal neural

- network for pitch processing in congenital amusia. *Cereb. Cortex* 21, 292–299.
- Hyde, K.L., Peretz, I., Zatorre, R.J., 2008. Evidence for the role of the right auditory cortex in fine pitch resolution. *Neuropsychologia* 46, 632–639.
- Hyde, K.L., Zatorre, R.J., Griffiths, T.D., Lerch, J.P., Peretz, I., 2006. Morphometry of the amusic brain: a two-site study. *Brain* 129, 2562–2570.
- Hyde, K.L., Lerch, J.P., Zatorre, R.J., Griffiths, T.D., Evans, A.C., Peretz, I., 2007. Cortical thickness in congenital amusia: when less is better than more. *J. Neurosci.* 27, 13028–13032.
- Ivanova, M.V., Isaev, D.Y., Dragoy, O.V., Akinina, Y.S., Petrushevskiy, A.G., Fedina, O.N., et al., 2016. Diffusion-tensor imaging of major white matter tracts and their role in language processing in aphasia. *Cortex* 85, 165–181.
- Jafari, Z., Esmaili, M., Delbari, A., Mehrpour, M., Mohajerani, M.H., 2017. Post-stroke acquired amusia: a comparison between right- and left-brain hemispheric damages. *NeuroRehabilitation* 40, 233–241.
- Jamison, H.L., Watkins, K.E., Bishop, D.V., Matthews, P.M., 2006. Hemispheric specialization for processing auditory nonspeech stimuli. *Cereb. Cortex* 16, 1266–1275.
- Jerde, T.A., Childs, S.K., Handy, S.T., Nagode, J.C., Pardo, J.V., 2011. Dissociable systems of working memory for rhythm and melody. *Neuroimage* 57, 1572–1579.
- Johannes, S., Jobges, M.E., Dengler, R., Münte, T.F., 1998. Cortical auditory disorders: a case of non-verbal disturbances assessed with event-related brain potentials. *Behav. Neurol.* 11, 55–73.
- Koelsch, S., 2014. Brain correlates of music-evoked emotions. *Nat. Rev. Neurosci.* 15, 170–180.
- Koelsch, S., 2011. Toward a neural basis of music perception - a review and updated model. *Front. Psychol.* 2, 110.
- Koelsch, S., Siebel, W.A., 2005. Towards a neural basis of music perception. *Trends Cogn. Sci. (Regul. Ed.)* 9, 578–584.
- Kohlmetz, C., Altenmüller, E., Schuppert, M., Wieringa, B.M., Münte, T.F., 2001. Deficit in automatic sound-change detection may underlie some music perception deficits after acute hemispheric stroke. *Neuropsychologia* 39, 1121–1124.
- Kummerer, D., Hartwigsen, G., Kellmeyer, P., Glauche, V., Mader, I., Kloppel, S., et al., 2013. Damage to ventral and dorsal language pathways in acute aphasia. *Brain* 136, 619–629.
- LaCroix, A.N., Diaz, A.F., Rogalsky, C., 2015. The relationship between the neural computations for speech and music perception is context-dependent: an activation likelihood estimate study. *Front. Psychol.* 6, 1138.
- Leveque, Y., Teyssier, P., Bouchet, P., Bigand, E., Caclin, A., Tillmann, B., 2018. Musical emotions in congenital amusia: impaired recognition, but preserved emotional intensity. *Neuropsychologia* 32, 880–894.
- Leveque, Y., Fauvel, B., Groussard, M., Caclin, A., Albouy, P., Platel, H., et al., 2016. Altered intrinsic connectivity of the auditory cortex in congenital amusia. *J. Neurophysiol.* 116, 88–97.
- Lévêque, Y., Schön, D., 2015. Modulation of the motor cortex during singing-voice perception. *Neuropsychologia* 70, 58–63.
- Liu, F., Patel, A.D., Fourcin, A., Stewart, L., 2010. Intonation processing in congenital amusia: discrimination, identification and imitation. *Brain* 133, 1682–1693.
- Lopez-Barroso, D., de Diego-Balaguer, R., Cunillera, T., Camara, E., Münte, T.F., Rodríguez-Fornells, A., 2011. Language learning under working memory constraints correlates with microstructural differences in the ventral language pathway. *Cereb. Cortex* 21, 2742–2750.
- Loui, P., 2015. A dual-stream neuroanatomy of singing. *Music Percept.* 32, 232–241.
- Loui, P., Alsop, D., Schlaug, G., 2009. Tone deafness: a new disconnection syndrome? *J. Neurosci.* 29, 10215–10220.
- Loui, P., Guenther, F.H., Mathys, C., Schlaug, G., 2008. Action-perception mismatch in tone-deafness. *Curr. Biol.* 18, R331–2.
- Loui, P., Patterson, S., Sachs, M.E., Leung, Y., Zeng, T., Przynsinda, E., 2017. White matter correlates of musical anhedonia: implications for evolution of music. *Front. Psychol.* 8, 1664.
- Maess, B., Koelsch, S., Gunter, T.C., Friederici, A.D., 2001. Musical syntax is processed in Broca's area: an MEG study. *Nat. Neurosci.* 4, 540–545.
- Makris, N., Goldstein, J.M., Kennedy, D., Hodge, S.M., Caviness, V.S., Faraone, S.V., et al., 2006. Decreased volume of left and total anterior insular lobule in schizophrenia. *Schizophr. Res.* 83, 155–171.
- Mandell, J., Schulze, K., Schlaug, G., 2007. Congenital amusia: an auditory-motor feedback disorder? *Restor. Neurol. Neurosci.* 25, 323–334.
- Martinez-Molina, N., Mas-Herrero, E., Rodríguez-Fornells, A., Zatorre, R.J., Marco-Pallares, J., 2019. White matter microstructure reflects individual differences in music reward sensitivity. *J. Neurosci.* 39, 5018–5027.
- Martinez-Molina, N., Mas-Herrero, E., Rodríguez-Fornells, A., Zatorre, R.J., Marco-Pallares, J., 2016. Neural correlates of specific musical anhedonia. *Proc. Natl. Acad. Sci. U. S. A.* 113, E7337–E7345.
- Mas-Herrero, E., Marco-Pallares, J., Lorenzo-Seva, U., Zatorre, R.J., Rodríguez-Fornells, A., 2013. Individual differences in music reward experiences. *Music Perception* 31, 118–138.
- Mazzoni, M., Moretti, P., Pardossi, L., Vista, M., Muratorio, A., Puglioli, M., 1993. A case of music imperception. *J. Neurol. Neurosurg. Psychiatry* 56, 322.
- Mazzucchi, A., Marchini, C., Budai, R., Parma, M., 1982. A case of receptive amusia with prominent timbre perception defect. *J. Neurol. Neurosurg. Psychiatry* 45, 644–647.
- Mendez, M.F., 2001. Generalized auditory agnosia with spared music recognition in a left-hander. Analysis of a case with a right temporal stroke. *Cortex* 37, 139–150.
- Mirman, D., Chen, Q., Zhang, Y., Wang, Z., Faseyitan, O.K., Coslett, H.B., et al., 2015. Neural organization of spoken language revealed by lesion-symptom mapping. *Nat. Commun.* 6, 6762.
- Mitchell, R.L., Ross, E.D., 2008. fMRI evidence for the effect of verbal complexity on lateralisation of the neural response associated with decoding prosodic emotion. *Neuropsychologia* 46, 2880–2887.
- Münte, T.F., Schuppert, M., Johannes, S., Wieringa, B.M., Kohlmetz, C., Altenmüller, E., 1998. Brain potentials in patients with music perception deficits: evidence for an early locus. *Neurosci. Lett.* 256, 85–88.
- Musso, M., Weiller, C., Horn, A., Glauche, V., Umarova, R., Hennig, J., et al., 2015. A single dual-stream framework for syntactic computations in music and language. *Neuroimage* 117, 267–283.
- Norman-Haignere, S., Kanwisher, N.G., McDermott, J.H., 2015. Distinct cortical pathways for music and speech revealed by Hypothesis-Free voxel decomposition. *Neuron* 88, 1281–1296.
- Norman-Haignere, S.V., Albouy, P., Caclin, A., McDermott, J.H., Kanwisher, N.G., Tillmann, B., 2016. Pitch-responsive cortical regions in congenital amusia. *J. Neurosci.* 36, 2986–2994.
- Omigie, D., Müllensiefen, D., Stewart, L., 2012. The experience of music in congenital amusia. *Music Percept.* 30, 1–18.
- Özdemir, E., Norton, A., Schlaug, G., 2006. Shared and distinct neural correlates of singing and speaking. *Neuroimage* 33, 628–635.
- Patel, A.D., 2003. Language, music, syntax and the brain. *Nat. Neurosci.* 6, 674–681.
- Perani, D., Saccuman, M.C., Scifo, P., Anwander, A., Spada, D., Baldoli, C., et al., 2011. Neural language networks at birth. *Proc. Natl. Acad. Sci. U. S. A.* 108, 16056–16061.
- Peretz, I., 2016. Neurobiology of congenital amusia. *Trends Cogn. Sci.* 20, 857–867.
- Peretz, I., 1990. Processing of local and global musical information by unilateral brain-damaged patients. *Brain* 113 (Pt 4), 1185–1205.
- Peretz, I., Coltheart, M., 2003. Modularity of music processing. *Nat. Neurosci.* 6, 688–691.
- Peretz, I., Brattico, E., Tervaniemi, M., 2005. Abnormal electrical brain responses to pitch in congenital amusia. *Ann. Neurol.* 58, 478–482.
- Peretz, I., Champod, A.S., Hyde, K., 2003. Varieties of musical disorders. The montreal battery of evaluation of amusia. *Ann. N. Y. Acad. Sci.* 999, 58–75.
- Peretz, I., Belleville, S., Fontaine, S., 1997. Dissociations between music and language functions after cerebral resection: a new case of amusia without aphasia. *Can. J. Exp. Psychol.* 51, 354–368.
- Peretz, I., Brattico, E., Järvenpää, M., Tervaniemi, M., 2009. The amusic brain: in tune, out of key, and unaware. *Brain* 132, 1277–1286.
- Piccirilli, M., Sciarma, T., Luzzi, S., 2000. Modularity of music: evidence from a case of pure amusia. *J. Neurol. Neurosurg. Psychiatry* 69, 541–545.
- Price, C.J., Friston, K.J., 2002. Degeneracy and cognitive anatomy. *Trends Cogn. Sci.* 6, 416–421.
- Rauschecker, J.P., 2014. Is there a tape recorder in your head? How the brain stores and retrieves musical melodies. *Front. Syst. Neurosci.* 8, 149.
- Rauschecker, J.P., Scott, S.K., 2009. Maps and streams in the auditory cortex: nonhuman primates illuminate human speech processing. *Nat. Neurosci.* 12, 718–724.
- Rauschecker, J.P., Tian, B., 2000. Mechanisms and streams for processing of "what" and "where" in auditory cortex. *Proc. Natl. Acad. Sci. U. S. A.* 97, 11800–11806.
- Rogalsky, C., Rong, F., Saberi, K., Hickok, G., 2011. Functional anatomy of language and music perception: temporal and structural factors investigated using functional magnetic resonance imaging. *J. Neurosci.* 31, 3843–3852.
- Rorden, C., Karnath, H.O., 2004. Using human brain lesions to infer function: a relic from a past era in the fMRI age? *Nat. Rev. Neurosci.* 5, 813–819.
- Ross, E.D., 2010. Cerebral localization of functions and the neurology of language: fact versus fiction or is it something else? *Neuroscientist* 16, 222–243.
- Ross, E.D., Monnot, M., 2008. Neurology of affective prosody and its functional-anatomic organization in right hemisphere. *Brain Lang.* 104, 51–74.
- Royal, I., Vuvan, D.T., Zendel, B.R., Robitaille, N., Schonwiesner, M., Peretz, I., 2016. Activation in the right inferior parietal lobule reflects the representation of musical structure beyond simple pitch discrimination. *PLoS One* 11, e0155291.
- Sammler, D., Grosbras, M.H., Anwander, A., Bestelmeyer, P.E., Belin, P., 2015. Dorsal and ventral pathways for prosody. *Curr. Biol.* 25, 3079–3085.
- Sammler, D., Cunitz, K., Gierhan, S.M.E., Anwander, A., Adermann, J., Meixensberger, J., et al., 2018. White matter pathways for prosodic structure building: a case study. *Brain Lang.* 183, 1–10.
- Samson, F., Zeffiro, T.A., Toussaint, A., Belin, P., 2011. Stimulus complexity and categorical effects in human auditory cortex: an activation likelihood estimation meta-analysis. *Front. Psychol.* 1, 241.
- Samson, Y., Belin, P., Zilbovicius, M., Remy, P., van Eeckhout, P., Rancurel, G., 1999. Mechanisms of aphasia recovery and brain imaging. *Rev. Neurol. (Paris)* 155, 725–730.
- Särkämö, T., Tervaniemi, M., Soinila, S., Autti, T., Silvennoinen, H.M., Laine, M., et al., 2009. Cognitive deficits associated with acquired amusia after stroke: a neuropsychological follow-up study. *Neuropsychologia* 47, 2642–2651.
- Särkämö, T., Tervaniemi, M., Soinila, S., Autti, T., Silvennoinen, H.M., Laine, M., et al., 2010. Auditory and cognitive deficits associated with acquired amusia after stroke: a magnetoencephalography and neuropsychological follow-up study. *PLoS One* 5, e15157.
- Satoh, M., Nakase, T., Nagata, K., Tomimoto, H., 2011. Musical anhedonia: selective loss of emotional experience in listening to music. *Neurocase* 17, 410–417.
- Satoh, M., Kato, N., Tabei, K.I., Nakano, C., Abe, M., Fujita, R., et al., 2016. A case of musical anhedonia due to right putaminal hemorrhage: a disconnection syndrome between the auditory cortex and insula. *Neurocase* 22, 518–525.
- Saur, D., Lange, R., Baumgaertner, A., Schraknepper, V., Willmes, K., Rijntjes, M., et al., 2006. Dynamics of language reorganization after stroke. *Brain* 129, 1371–1384.
- Schlaug, G., Marchina, S., Norton, A., 2009. Evidence for plasticity in white-matter tracts of patients with chronic Broca's aphasia undergoing intense intonation-based speech therapy. *Ann. N. Y. Acad. Sci.* 1169, 385–394.
- Schlaug, G., Norton, A., Marchina, S., Zipse, L., Wan, C.Y., 2010. From singing to speaking: facilitating recovery from nonfluent aphasia. *Future Neurol.* 5, 657–665.
- Schmithorst, V.J., 2005. Separate cortical networks involved in music perception:

- preliminary functional MRI evidence for modularity of music processing. *Neuroimage* 25, 444–451.
- Schuppert, M., Münte, T.F., Wieringa, B.M., Altenmüller, E., 2000. Receptive amusia: evidence for cross-hemispheric neural networks underlying music processing strategies. *Brain* 123 (Pt 3), 546–559.
- Sidtis, J.J., Volpe, B.T., 1988. Selective loss of complex-pitch or speech discrimination after unilateral lesion. *Brain Lang.* 34, 235–245.
- Sihvonen, A.J., Ripollés, P., Rodríguez-Fornells, A., Soinila, S., Särkämö, T., 2017a. Revisiting the neural basis of acquired amusia: structural changes underlying amusia recovery. *Front. Neurosci.* 11.
- Sihvonen, A.J., Särkämö, T., Leo, V., Tervaniemi, M., Altenmüller, E., Soinila, S., 2017b. Music-based interventions in neurological rehabilitation. *Lancet Neurol.* 16, 648–660.
- Sihvonen, A.J., Ripollés, P., Leo, V., Rodríguez-Fornells, A., Soinila, S., Särkämö, T., 2016. Neural basis of acquired Amusia and its recovery after stroke. *J. Neurosci.* 36, 8872–8881.
- Sihvonen, A.J., Ripollés, P., Särkämö, T., Leo, V., Rodríguez-Fornells, A., Saunavaara, J., et al., 2017c. Tracing the neural basis of music: deficient structural connectivity underlying acquired amusia. *Cortex.*
- Sihvonen, A.J., Särkämö, T., Ripollés, P., Leo, V., Saunavaara, J., Parkkola, R., et al., 2017d. Functional neural changes associated with acquired amusia across different stages of recovery after stroke. *Sci. Rep.* 7 (11390) 017-11841-6.
- Sperber, C., Wiesen, D., Karnath, H.O., 2018. An empirical evaluation of multivariate lesion behaviour mapping using support vector regression. *Hum. Brain Mapp.*
- Stewart, L., 2008. Fractionating the musical mind: insights from congenital amusia. *Curr. Opin. Neurobiol.* 18, 127–130.
- Stewart, L., von Kriegstein, K., Warren, J.D., Griffiths, T.D., 2006. Music and the brain: disorders of musical listening. *Brain* 129, 2533–2553.
- Tervaniemi, M., Szameitat, A.J., Kruck, S., Schroger, E., Alter, K., De Baene, W., et al., 2006. From air oscillations to music and speech: functional magnetic resonance imaging evidence for fine-tuned neural networks in audition. *J. Neurosci.* 26, 8647–8652.
- Thiebaut de Schotten, M., Dell'Acqua, F., Valabregue, R., Catani, M., 2012. Monkey to human comparative anatomy of the frontal lobe association tracts. *Cortex* 48, 82–96.
- Thiebaut de Schotten, M., Kinkingnehun, S., Delmaire, C., Lehericy, S., Duffau, H., Thivard, L., et al., 2008. Visualization of disconnection syndromes in humans. *Cortex* 44, 1097–1103.
- Thompson, W.F., Marin, M.M., Stewart, L., 2012. Reduced sensitivity to emotional prosody in congenital amusia rekindles the musical protolanguage hypothesis. *Proc. Natl. Acad. Sci. U. S. A.* 109, 19027–19032.
- Tillmann, B., Albouy, P., Caclin, A., 2015. Congenital amusias. *Handb. Clin. Neurol.* 129, 589–605.
- Tillmann, B., Koelsch, S., Escoffier, N., Bigand, E., Lalitte, P., Friederici, A.D., et al., 2006. Cognitive priming in sung and instrumental music: activation of inferior frontal cortex. *Neuroimage* 31, 1771–1782.
- Toivaiainen, P., Alluri, V., Brattico, E., Wallentin, M., Vuust, P., 2014. Capturing the musical brain with Lasso: dynamic decoding of musical features from fMRI data. *Neuroimage* 88, 170–180.
- Tzortzis, C., Goldblum, M.C., Dang, M., Forette, F., Boller, F., 2000. Absence of amusia and preserved naming of musical instruments in an aphasic composer. *Cortex* 36, 227–242.
- Tzourio-Mazoyer, N., Landeau, B., Papathanassiou, D., Crivello, F., Etard, O., Delcroix, N., et al., 2002. Automated anatomical labeling of activations in SPM using a macroscopic anatomical parcellation of the MNI MRI single-subject brain. *Neuroimage* 15, 273–289.
- Uetsuki, S., Kinoshita, H., Takahashi, R., Obata, S., Kakigi, T., Wada, Y., et al., 2016. A case of expressive-vocal amusia in a right-handed patient with left hemispheric cerebral infarction. *Brain Cogn.* 103, 23–29.
- van den Heuvel, M.P., Sporns, O., 2013. Network hubs in the human brain. *Trends Cogn. Sci.* 17, 683–696.
- Wakana, S., Caprihan, A., Panzenboeck, M.M., Fallon, J.H., Perry, M., Gollub, R.L., et al., 2007. Reproducibility of quantitative tractography methods applied to cerebral white matter. *Neuroimage* 36, 630–644.
- Wan, C.Y., Zheng, X., Marchina, S., Norton, A., Schlaug, G., 2014. Intensive therapy induces contralateral white matter changes in chronic stroke patients with Broca's aphasia. *Brain Lang.* 136, 1–7.
- Warren, J.D., Jennings, A.R., Griffiths, T.D., 2005. Analysis of the spectral envelope of sounds by the human brain. *Neuroimage* 24, 1052–1057.
- Wilbiks, J.M., Vuvan, D.T., Girard, P.Y., Peretz, I., Russo, F.A., 2016. Effects of vocal training in a musicophile with congenital amusia. *Neurocase* 22, 526–537.
- Wildgruber, D., Ackermann, H., Kreifelts, B., Ethofer, T., 2006. Cerebral processing of linguistic and emotional prosody: fMRI studies. *Prog. Brain Res.* 156, 249–268.
- Zatorre, R.J., Salimpoor, V.N., 2013. From perception to pleasure: music and its neural substrates. *Proc. Natl. Acad. Sci. U. S. A.* 110 (Suppl 2), 10430–10437.
- Zatorre, R.J., Belin, P., Penhune, V.B., 2002. Structure and function of auditory cortex: music and speech. *Trends Cogn. Sci.* 6, 37–46.
- Zavaglia, M., Forkert, N.D., Cheng, B., Gerloff, C., Thomalla, G., Hilgetag, C.C., 2015. Mapping causal functional contributions derived from the clinical assessment of brain damage after stroke. *Neuroimage Clin.* 9, 83–94.
- Zendel, B.R., Lagrois, M.E., Robitaille, N., Peretz, I., 2015. Attending to pitch information inhibits processing of pitch information: the curious case of amusia. *J. Neurosci.* 35, 3815–3824.